

Management of type B2 and B3 post-operative proximal periprosthetic femoral fractures, Oghara experience.

*Enemudo, R.E.T.¹, Edomwonyi, E.O.², Odatuwa-Omagbemi, D.O.¹, Obumse, A.T.¹, Awa, M.M.³

Abstract

Objective: To report the outcome of treatment of Types B2 and B3 Post-operative Periprosthetic proximal femoral fracture (PPFF) in four patients treated in Delta State University Teaching Hospital, Oghara, Delta State, using Vancouver classification of Duncan and Masri.

Methodology: A retrospective study of four cases managed in this hospital. Information retrieved from case notes were sex, age, duration of prosthesis, treatment given, complications and outcome of treatment.

Result: A total of 4 patients were reviewed in the study, 2 males and 2 females with a M: F of 1: 1. Duration of the implant before treatment was 5-12 years (mean of 8.3years). Age range was 60-83years (mean of 67.5 years). Two patients had Type B2 and two had Type B3. Average intraoperative blood loss was 1 litre. Duration of surgery was 3-4 hours. Duration of hospital stay was between 3 weeks and 5 months. The complications seen were primary haemorrhage, wound infection, hip dislocation and pulmonary embolism. The outcome was good for 3 patients and fair in 1, using Harris Hip Score.

Conclusion: Vancouver classification of Duncan and Masri is effective in the treatment of PPFF.

Key words; Periprosthetic femoral fracture, Long stem hip prosthesis, Vancouver classification, osteolysis.

*Corresponding author

Enemudo, R.E.T

ORCID-NO: <http://orcid.org/0000-0003-3830-0933>

Email: royenemudo11@gmail.com

¹Delta State University Teaching Hospital, Oghara, Delta State.

²Irrua Specialist Teaching Hospital, Irrua, Edo State.

³Supreme Grace Medicals, Okpanam, Delta State.

Received: August 28, 2020

Accepted: December 12, 2020

Published: March 31, 2021

Research Journal of Health Sciences subscribed to terms and conditions of Open Access publication. Articles are distributed under the terms of Creative Commons Licence (CC BY-NC-ND 4.0). (<http://creativecommons.org/licenses/by-nc-nd/4.0>).

<http://dx.doi.org/10.4314/rejhs.v9i1.6>

Prise en charge des fractures fémorales péri prothétiques proximales postopératoires de type B2 et B3, expérience d'Oghara

*Enemudo, R.E.T.¹, Edomwonyi, E.O.², Odatuwa-Omagbemi, D.O.¹, Obumse, A.T.¹, Awa, M.M.³

Résumé

Objectif de l'étude : Rendre compte des résultats du traitement des fractures fémorales proximales (TFFP) postopératoires des types B2 et B3 chez quatre patients traités au Delta State University Teaching Hospital, Oghara, Delta State, en utilisant la classification de Vancouver de Duncan et Masri.

Méthode de l'étude: Une étude rétrospective de quatre cas gérés dans cet hôpital. Les informations extraites des notes de cas étaient le sexe, l'âge, la durée de la prothèse, le traitement administré, les complications et l'issue du traitement.

Résultat de l'étude : Un total de 4 patients ont été revus dans l'étude, 2 hommes et 2 femmes avec un M: F de 1: 1. La durée de l'implant avant le traitement était de 5 à 12 ans (moyenne de 8,3 ans). La tranche d'âge était de 60 à 83 ans (moyenne de 67,5 ans). Deux patients avaient le type B2 et deux avaient le type B3. La perte sanguine per opératoire moyenne était de 1 litre. La durée de la chirurgie était de 3 à 4 heures. La durée du séjour à l'hôpital était comprise entre 3 semaines et 5 mois. Les complications observées étaient une hémorragie primaire, une infection de la plaie, une luxation de la hanche et une embolie pulmonaire. Le résultat était bon pour 3 patients et passable pour 1'en utilisant le Harris Hip Score.

Conclusion: la classification de Vancouver de Duncan et Masri est efficace dans le traitement du TFFP.

Mots-clés ; Fracture fémorale péri prothétique, prothèse de hanche à tige longue, classification de Vancouver, ostéolyse

*Corresponding author

Enemudo, R.E.T

ORCID-NO: <http://orcid.org/0000-0003-3830-0933>

Email: royenemudo11@gmail.com

¹Delta State University Teaching Hospital, Oghara, Delta State.

²Irrua Specialist Teaching Hospital, Irrua, Edo State.

³Supreme Grace Medicals, Okpanam, Delta State.

Received: August 28, 2020

Accepted: December 12, 2020

Published: March 31, 2021

Research Journal of Health Sciences subscribed to terms and conditions of Open Access publication. Articles are distributed under the terms of Creative Commons Licence (CC BY-NC-ND 4.0). (<http://creativecommons.org/licenses/by-nc-nd/4.0>).

<http://dx.doi.org/10.4314/rejhs.v9i1.6>

INTRODUCTION

Periprosthetic femoral fractures are serious complications associated with partial or total hip arthroplasty (1,2). It is commonly a post-operative complication but can also occur intra-operatively. They usually occur some years after surgery. The commonest reason is due to osteolysis arising from the prosthesis eroding the bone and subsequent fracturing of the osteolytic bone (2). The force that causes the fracture is usually trivial akin to pathological fracture. The proportion of arthroplasties being done has increased over the years and coupled with poor bone quality and increase in life span of the elderly patients undertaking these surgeries, we are beginning to see some of these complications among this subset of patients (2). Periprosthetic fractures that occur intra-operatively are due to marked osteoporosis and technical factors like cortical perforation during reaming (3,4). During manipulation like reduction of joints or fractures, bones can break around prosthesis (3).

The incidence of periprosthetic femoral fracture in Sweden is 4.1% and the number of this procedure done annually is steadily rising (1,5). Periprosthetic proximal femoral fracture predisposes affected patients to pressure sores, haemorrhage during surgical intervention and life-threatening complication of thromboembolism (1). There is also added burden from nursing care and loss of livelihood for those at the productive age group. This poses a lot of economic burden on the health care system of a nation (1). A need to develop a treatment protocol that is effective and efficient to tackle this inevitable problem of the elderly cannot be over emphasized.

Several classifications have been proposed to help grade the fracture and proffer the best treatment option. Duncan and Masri developed the Vancouver classification of proximal femoral periprosthetic fracture (6,7). To date, this is the best as it considers the fracture site, stability of the prosthesis in-situ and the quality of the bone stock. It is graded into 3 Types A, B and C. With A having 2 subtypes and B having 3 subtypes and C, one subtype (6,7). Other classifications have been a modification of the Vancouver classification that just try to fill in the gaps left by the Vancouver classification. An example is the New Unified Classification System [UFS] by Duncan and Haddad (7). The Vancouver classification has made grading of these fractures very easy and treatment options also very easy to decide too by the orthopaedic surgeons [6,7]. The treatment options available

include use of long-stem hip prosthesis, bone cement for loose prosthesis and locking plate and screw plus cerclage wiring (6,7).

In this study, we want to highlight our experience in post-operative proximal periprosthetic femoral fracture treatment for Type B2 and B3 in Delta State University Teaching Hospital, Oghara, Delta State, Nigeria.

MATERIALS AND METHOD.

This is a retrospective study of 4 cases managed in DELSUTH, Oghara over a 6-year period (May 2013-April 2019). Delta State University Teaching Hospital is a tertiary health institution located in the south-south geopolitical zone of Nigeria. It is equipped with relevant equipment like digital plain radiographs, CT-scan, mammogram, fluoroscopy machine and magnetic resonance imaging machine. The Center cares for patients in the state as well as those from neighbouring states for their orthopaedic and other medical issues.

Information for the study was obtained from patient case notes. They include social demographic data (age, sex, occupation), aetiology, duration of implant in the body before presentation, any co-morbidity, treatment offered, complications following treatment and outcome of treatment. Outcome was assessed with Harris Hip Score. Consent was obtained from patients. Ethical clearance was obtained from the Institution Research Ethical Committee. Results were analysed using a simple statistical method.

Pocedure

Patient was given combined epidural and spinal anaesthesia. Broad spectrum antibiotics was administered (ceftriaxone and metronidazole). Patient was positioned in the lateral position, with the affected hip uppermost. Patient's limb was cleaned and draped. A posterolateral approach was used to expose the hip joint and the wound extended distally to expose the fracture site. The gluteus medius muscle fibres were split along its fibres anteriorly to expose the joint capsule anteriorly. The capsule was incised in a cruciate shape to expose the hip prosthesis. The hip was dislocated anteriorly by external rotation with the support of a murphy skid. The prosthesis was removed from the femur. The fracture site was identified and exposed. Edges were refreshed, reduced and stabilized with plate and screws [(locking plate), unicortical screws were used for greater trochanter region, while bicortical screws were used below the

prosthesis] and fixation reinforced with multiple cerclage wires. The plate fixation was used for the two Type B3 fractures. A short-stem hip prosthesis stabilized in place by bone cement was used for one Type B3 case (83-year old patient). A long-stem hip prosthesis of determined head size was used to replace the short regular prosthesis previously used that was loose for Type B2 PPF and the other Type B3 fracture. The long stem prosthesis we used in this study was a hybrid implant made from a bipolar hip prosthesis and a cut k-nail that was dilated at one end to admit the stem of the bipolar hip prosthesis. This prosthesis was hammered into the cut k-nail at the dilated end to have a tight fit. Bone cement was not used for the Type B2 cases and one Type B3 fracture, just long stem hip prosthesis. The marrow cavity was reamed with a rasp, suctioned dry for all the patients. The marrow cavity was also reamed with a k-nail reamer to admit the k-nail attachment of the long stem hip prosthesis. The marrow of the 83-year old woman that used the short stem prosthesis was filled with bone cement before the prosthesis was inserted into it. The prosthesis was held in place until the cement was set. Bone cement debris was removed and wound irrigated copiously with normal saline. The hip joint was reduced and wound was closed up in layers using vicryl suture for deep layers, drain was inserted at subcutaneous layer and skin closed with nylon sutures. An above knee Plaster of Paris cast with anti-rotation bar was applied to prevent flexion and rotation of the hip to protect the fracture fixation. Post-operation check x-ray was done by c-arm in theatre and found to be satisfactory.

Patients were placed on the following; broad spectrum antibiotic ceftriaxone and metronidazole for 48 hours parenterally thereafter oral forms for 10 days, anti-coagulants; subcutaneous clexane 40mg daily for immediate 5 days and warfarin tablets 2.5mg daily afterwards. Analgesics given were diclofenac and tramadol or tramadol and paracetamol for those that have peptic ulcer disease. All patients were given Vitamin D3 (1000IU daily), Vitamin C (600mg daily) and calcium supplements (1000mg daily). Stitches were removed after 2 weeks with no wound dehiscence or infection seen. Patients were on bed rest for 3weeks for Type B2 and 6 weeks for Type B3 fractures before they were ambulated on partial weight bearing with either a pair of axillary crutches or Zimmer walking frame. Patient did well and were discharged home to continue out-patient care. Follow up continued from the period between

6months to 6 years now. Patients were monitored for hip pains and normal functions of daily living using Harris Hip Score.

RESULTS

A total of 4 patients were seen in our study, 2 males and 2 females (M:F =1:1). Age range was 60-83 years with a mean age of 67.5years. One of the patients had tertiary education, while two had secondary education. The oldest of them, though did not have formal education, has children who are well educated and she can interact in pidgin English. One was a welder, two were traders (one was retired), one was a contractor.

Three (3) of the patients were hypertensive, none had diabetes mellitus. None smoked. All had osteolysis of the proximal femur. Fracture was caused by trivial trauma in all the patients. Two patients had Type B2 and the other two had Type B3. Average intraoperative blood loss was 1 litre for all the patients. Duration of surgery was 3-4 hours, (average of 3.5 hours). Duration of hospital stay was 3 weeks for Type B2 and 6weeks and 5 months for the Type B3 fractures. The complications seen in this study were primary haemorrhage, wound infection, recurrent hip dislocation and pulmonary embolism. The outcome of the treatment was good for 3 patients and fair in 1 point using Harris Hip Score (HHS). The average HHS score was 80 points [range of 71-88 points]

DISCUSSION

Periprosthetic femoral fracture is a known complication of arthroplasty surgery (1,2,3). It has become part of the regular cases being operated in western countries (1,2,3). It is now gradually appearing in our patients that have been offered arthroplasty over the last decade. There is a need to appreciate this problem and plan ahead to provide the right treatment when they present. It is in this vein that Duncan and Masri came up with the Vancouver classification of periprosthetic femoral fracture. Up till now, the classification has made both assessment and decision on the right choice of treatment very easy (1,6,7). Based on the classification, the 4 cases in our study had Type B2 and B3 PPF, two each and following the same classification, we decided on the treatment options advised. The outcomes were successful.

In this study, we observed that the life span of hemiarthroplasty exposed to normal stress of daily living is 10-12 years while that subjected to abnormal stress lasted between 5-6

years [Table 1]. According to the Swedish National Hip Arthroplasty register, the average lifespan for primary arthroplasty is 7.4 years while for revision arthroplasty is 3.9 years (3). The risk factors identified in this study were postmenopausal factor seen in female, limb length discrepancy, carrying of heavy load, genu valgum deformity and knee osteoarthritis in the contralateral limb, elderly [Tables 1]. Similar risk factors were identified by other authors as responsible for the increased osteolysis, a prelude to pathological fracture (8,9). Trivial force from a fall or while trying to get up or sit down were identified in three of our cases in our study as the eventual cause of fracture in three of our patients. This agrees with the findings in the literature (8,9). Another risk factor is a previous history of fracture before the arthroplasty (3,8).

Non operative treatment is not an option as it yields poor outcome and exposes the patient to complications associated with prolonged bed stay (1). The treatment options given to the patients in this study were those prescribed for Type B2 and B3 [Table 2] by Duncan and Masri (6,7). This was long stem hip prosthesis, which in this study, was a hybrid long stem hip prosthesis made from a cut k-nail and a bipolar hip prosthesis. This implant was long enough to span the fracture site (by more than 3x the diameter of the shaft) and splint it for Type B2 fracture, while for Type B3, an additional protection from locking plate and screws and cerclage wiring were necessary to ensure the prosthesis was stable [Fig 2b]. The other Type B3 fracture was fixed with plate and screws and cerclage wiring. Bone cement was inserted to ensure stability of the short stem prosthesis. The risk of fracturing the femoral shaft during reaming that is necessary for the insertion of long stem prosthesis was high in the 83-year old woman because of marked osteoporosis. It did not allow us to use the long stem prosthesis [Fig 1b & 1c]. The normal stem prosthesis was inserted and stabilized by bone cement for her. All the patients did well with treatment options instituted. The other treatment offered to the patient with limb length discrepancy was Ilizarov technique [Fig 2b & 2c] while the patient with genu valgum deformity and severe osteoarthritis of the contralateral knee joint had corrective osteotomy and arthrodesis of contralateral knee joint done for her [Table 1]. They were done to remove the stress these problems exerted on the prosthetic hip joint to prevent failure of the revision surgery.

The different types of PPF have different treatment options adopted by several

authors (10,11,12). For type A, Type AL is less important and is managed conservatively by bed rest and physiotherapy (1,6,7). Type AG is important and is fixed to ensure abduction of the hip joint is not affected and also to prevent recurrent hip dislocation. Transfixion with cancellous lag screw and a washer or Tension band wiring can be done for Type AG (1,6,7). The use of locking plate fixation is recommended for stable Type B1 fracture (10). Long stem hip prostheses have been used for Type B2 fractures (14,15). The treatment for Type C fractures, which occur well below the tip of the stem and does not involve the prosthesis, include use of locking plate, dynamic compression plate and cerclage wires (13,14,15). Retrograde nailing has also been used too (14,15). Proximal femoral replacement commonly used for neoplastic destruction of the proximal end of the femur is rarely used for Type B3 PPF where there is severe bone loss (16). Klein et al reported 21 cases with positive results (16). The problems associated with this procedure are dislocation, wound infections, graft disease and graft rejection (16). Tsiridis reported success in 144 patients he treated with impaction grafting of morselized cancellous bone graft for Type B2 and 3 PPF (17). Chandler used cortical strut allograft fixed with cables to treat 19 patients with Types B2 & B3 and recorded excellent results in 16 patients after 5 months (18).

Gallagher reported the contribution of deficiency of vitamin D and Calcium in PPF in this category of patients, especially the postmenopausal patients (19). They had marked osteoporosis and osteopaenia. He observed positive results in patients who had vitamins (C and D) and calcium supplements in their treatment protocol and advocated for the treatment protocol in these patients. This protocol was used in the patients in this case study.

The complications seen in this study were primary haemorrhage, pulmonary embolism, recurrent dislocation and wound infection [Table 2]. All these were seen in the male patient with Type B3. This is because of the two major surgeries done at different sessions and the prolonged bed stay. The distraction histiogenesis caused tearing of the skin and predisposed the patient to wound infection and possibly recurrent hip dislocation from the distracting force of the Ilizarov device. All the complications were addressed. The other patients all experienced primary haemorrhage while the 83-year old woman had constipation. Manual evacuation was done as laxative and liquid

paraffin could not resolve it. These complications seen in this study have been reported in other studies as well (1,4,9,19). Other post-operative complications seen in the literature but not found in our study include aseptic loosening, refracture, hip joint problems and a very long hospital stay (1,9,19). Different authors have advised that early detection by radiological screening when a patient notices implant loosening and immediate treatment will make treatment easier and cheaper as Type B3 fractures are complex, difficult to treat and the outcome is often poor (1,19). Type B3 is also associated with risk of death (1,20). The male patient in our study was faced with a near death experience from a pulmonary embolism incident [Table 6]. Drew et al in his study of 291 patients found a mortality of 13.1% and 15.8% at 12 and 18 months respectively (21). Bhattacharya found 11% mortality in his own study after 1 year for periprosthetic femoral fracture (22).

The hospital stay was between 3 weeks for type B2 and 6 weeks for Type B3. The male patient with Type B3 stayed for 5 months because of the limb lengthening procedure. His fracture healed while the regenerate continued to consolidate as he ambulated. Several authors have reported ambulating their patients from immediate days after surgery to 3 weeks post operation and fracture healing occurred from 3 months post-operation (1,23). The duration of hospital stay has been reported to be long for Type B3 PPF treatment by several authors (1,23).

The cost of treatment is determined by the type of fracture, time it takes to address the causative stress factor and the length of stay in the hospital, provided no new complication develops while on admission. This is not cheap at all in situations where health insurance does not cover this treatment like in some environment (23). This explains why we have a small number of patients in our study. A lot of patients that cannot afford arthroplasty end up in a traditional bone setter home (24). They may die in the process, as the right kind of treatment is not given to them. Some patients, who have had arthroplasty surgeries, do not live long to witness PPF because of low life expectancy (24). The quality of life and health care service in this country at present is far from optimal (24).

Despite the paucity of fund and non-availability of the right support from implant manufacturers and bioengineers in Nigeria to plan and design the appropriate implant system like the customized long stem hip prosthesis, as seen in developed western countries, we were

able to manage the patients seen in our study and achieve the successful outcome witnessed in developed clime. Our patients and relations were happy with the outcome and we felt fulfilled as well, though we could have done better if given the right support.

CONCLUSION

Periprosthetic femoral fracture is a common complication of hip arthroplasty. It is complex, difficult to manage and is life threatening. The prompt use of Vancouver classification and treatment protocol of PPF produced by Duncan and Masri gave us a good outcome. Government needs to put an ideal health insurance scheme in place, empower our bioengineers to adequately partner with orthopaedic surgeons and make the iron and steel company functional to face these challenges ahead.

Acknowledgement: We wish to appreciate the nurses in the Department of Orthopaedics and Trauma and physiotherapists of the Delta State University Teaching Hospital, Oghara that participated in the care of these patients and made the treatment outcome very successful.

Conflict of Interest: None.

REFERENCES

1. Marsland D, Mears S.C. A Review of Periprosthetic femoral Fractures Associated with Total Hip Arthroplasty. *Geriatric Orthop. Surg. Rehabil.* 2012;3(3):107-120
2. Berry DJ. Periprosthetic fractures associated with osteolysis: a problem on the rise. *J Arthroplasty.* 2003;18(3 suppl 1):107-111
3. Lindahl H, Malchau H, Herberts P, Garellick G. Periprosthetic femoral fractures: classification and demographics of 1049 periprosthetic femoral fractures from the Swedish National Hip Arthroplasty Register. *J Arthroplasty.* 2005;20(7):857-865
4. Lindahl H, Garellick G, Regner H, Herberts P, Malchau H. Three hundred and twenty-one periprosthetic femoral fractures. *J Bone Joint Surg Am.* 2006;88(6):1215-1222
5. Adolphson P, Jonsson U, Kalen R. Fractures of the ipsilateral femur after total hip arthroplasty. *Arch Orthop Trauma Surg.* 1987;106(6):353-357
6. Duncan CP, Masri BA. Fractures of the femur after hip replacement. *Instr Course Lect.* 1995; 44:293-304
7. Duncan CP, Haddad FS. The Unified Classification system (UCS): improving our understanding of periprosthetic fractures. *Bone Joint J.*, 2014;96-B:713-716.
8. Rayan F, Dodd M, Haddad FS. European validation of the Vancouver classification of

- periprosthetic proximal femoral fractures. *J Bone Joint Surg Br.* 2008;90(12):1576–1579
9. Franklin J, Malchau H. Risk factors for periprosthetic femoral fracture. *Injury.* 2007;38(6):655–660
 10. Chakravarthy J, Bansal R, Cooper J. Locking plate osteosynthesis for Vancouver Type B1 and Type C periprosthetic fractures of femur: a report on 12 patients. *Injury.* 2007;38(6):725–733
 11. Delasotta LA, Orozco F, Miller AG, Post Z, Ong A. Distal femoral fracture during primary total knee arthroplasty. *J Orthop Surg (Hong Kong)* 2015 Aug;23(2):202–204.
 12. Serocki JH, Chandler RW, Dorr LD. Treatment of fractures about hip prostheses with compression plating. *J Arthroplasty.* 1992;7(2):129–135
 13. Corten K, Vanrykel F, Bellemans J, Frederix PR, Simon JP, Broos PL. An algorithm for the surgical treatment of periprosthetic fractures of the femur around a well-fixed femoral component. *J Bone Joint Surg Br.* 2009;91(11):1424–1430
 14. Ricci WM, Bolhofner BR, Loftus T, Cox C, Mitchell S, Borrelli J., Jr Indirect reduction and plate fixation, without grafting, for periprosthetic femoral shaft fractures about a stable intramedullary implant. *J Bone Joint Surg Am.* 2005;87(10):2240–2245
 15. Klein GR, Parvizi J, Rapuri V et al. Proximal Femoral Replacement for the treatment of Periprosthetic fracture. *J Bone and Joint Surg. Am.* 2005;87(8):1777-1781
 16. Tsiridis E, Narvani AA, Haddad FS, Timperley JA, Gie GA. Impaction femoral allografting and cemented revision for periprosthetic femoral fractures. *J Bone Joint Surg Br.* 2004;86(8):1124–1132
 17. Chandler HP, Tigges RG. The role of allografts in the treatment of periprosthetic femoral fractures. *Instr Course Lect.* 1998; 47:257–264
 18. Gallagher JC, Sai AJ. Vitamin D insufficiency, deficiency, and bone health. *J Clin Endocrinol Metab.* 2010;95(6):2630–2633
 19. Zuurmond RG, van Wijhe W, van Raay JJ, Bulstra SK. High incidence of complications and poor clinical outcome in the operative treatment of periprosthetic femoral fractures: an analysis of 71 cases. *Injury.* 2010;41(6):629–633
 20. Lindahl H, Oden A, Garellick G, Malchau H. The excess mortality due to periprosthetic femur fracture. A study from the Swedish national hip arthroplasty register. *Bone.* 2007;40(5):1294–1298
 21. Drew JM, Griffin WL, Odum SM, et al. Survivorship after periprosthetic femur fracture: factors affecting outcome. *The Journal of Arthroplasty.* 2016; 31:1283–1288.
 22. Bhattacharyya T, Chang D, Meigs JB, et al. Mortality after periprosthetic fracture of the femur. *J Bone Joint Surg Am.* 2007;89(12):2658–62.
 23. Toogood PA, Vail TP. Periprosthetic Fractures. A Common Problem with a Disproportionately High Impact on Healthcare Resources. *J Arthroplasty.* 2015;30(10):1688–1691.
- Enemudo RET, Odatuwa-Omagbemi DO, Edomwonyi EO, Okeke MO. Management of Neglected Posterior Hip Dislocation Using a Two-Stage Procedure. *Nigerian Research Journal of Clinical Sciences.* 2015;5(2):119-125.

How to cite this article:

Enemudo R.E.T., Edomwonyi E.O., Odatuwa -Omagbemi D.O., Obumse A.T., Awa M.M. Management of type B2 and B3 post-operative proximal periprosthetic femoral fractures, Oghara experience. *Research Journal of Health Science*, 2021, 9(1): 52-60

Table 1: Social demographics and pathology

SEX / AGE (YEARS).	EDUCATIONAL STATUS	OCCUPATION	AETIOLOGY	DURATION OF ARTHROPLASTY/FRACTURE TYPE	COMORBIDITY
M / 64	Tertiary (university).	Businessman	Trivial fall	12years / Type B3	Hypertension, Urethral stricture and ipsilateral limb length shortening of 6cm
M / 65	Secondary school	Welder	Lifting a load	5 years / Type B2	Hypertension
F / 63	Secondary school	Trader	Trivial fall	6 years / Type B2	Contralateral genu valgum and knee osteoarthritis
F/ 83	No formal education*	Retired Trader	Trivial fall	10 years / Type B3	Hypertension

- Patient can speak pidgin English and has children that are well educated. Amongst them are a nurse and a gynaecologist.

Table 2: Treatment given, outcome and complications

S/N	TREATMENT	HHS	OUTCOME	COMPLICATIONS
1	Long-stem hip prosthesis + locking plate and screws + cerclage wiring + bone graft + Vitamin C & D3 + Calcium supplement + Ilizarov technique (Blood loss=1.2l, surgery time was 4hours)	71	Fair	Primary haemorrhage Tearing of skin, Wound infection Pulmonary embolism, Recurrent hip dislocation
2	Long-stem hip prosthesis + Vitamin C & D3 + Calcium supplement (Blood loss was 700ml. Surgery lasted 3 hours)	88	Good	Primary haemorrhage
3	Long-stem hip prosthesis + Vitamin C & D3 arthrodesis of the contralateral knee joint. (Blood loss was 800ml. Surgery lasted 3 hours)	81	Good	Primary haemorrhage
4	Replace the hip prosthesis with a bigger size + bone cement + plating of the fracture site + cerclage + Vit D3 + Calcium supplement. (Blood loss was 1.2 litres. Surgery lasted 4 hours).	80	Good	Primary haemorrhage

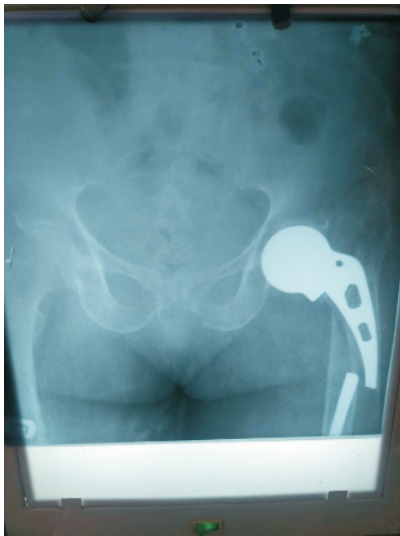

Figure 1a: Pre-op Xray of patient 4

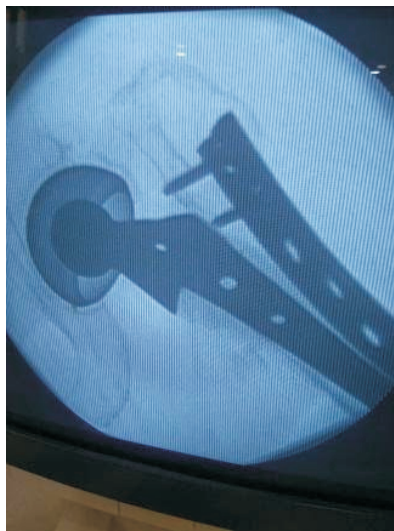


Figure 1b: Post-op Xray (optimal)



Figure 1c: Distal end of plate and prosthesis of patient 4

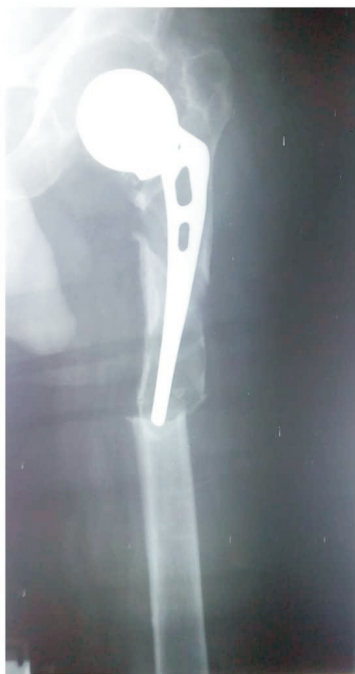

Figure 2a: Pre-op plain radiograph of patient 1

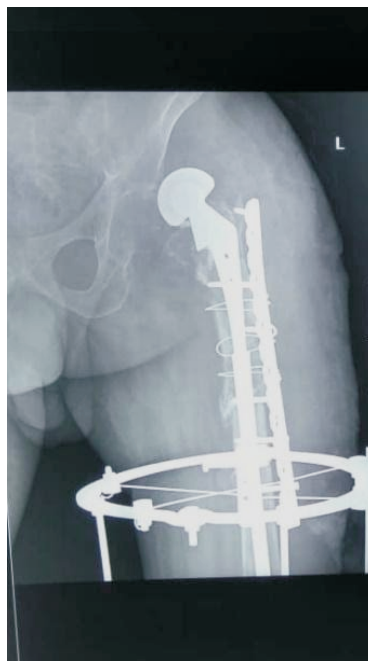


Figure 2b: Post-op plain radiograph of patient 1 with dislocated prosthesis

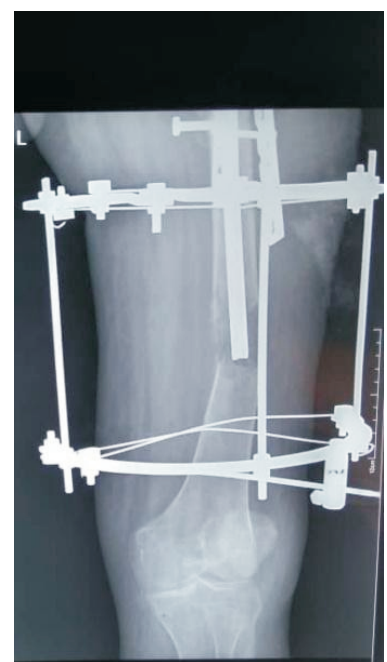

Figure 2c: Ilizarov frame showing regenerate