

Systemic Sclerosis – case report

*Alebiosu C.O.¹, Tadele D. Kebede.², James S.², Christopher D.²

Abstract

A case of Systemic Sclerosis is hereby reported, with brief review of literature emphasizing the clinical characteristics and management. Systemic Sclerosis is a connective tissue disorder affecting the skin, blood vessel, and visceral organs. Data relating to the occurrence of scleroderma is sparse or under-reported in Liberia. This is a case report of a patient suffering from scleroderma seen at the Jackson F. Doe Regional Referral Hospital, Tappita, Nimba County, Liberia in May, 2018. The goal was to document the clinical occurrence of scleroderma in Liberia. Literature was reviewed using key words including scleroderma, sclerosis, Liberia, West Africa. Data bases searched were AJOL and Pubmed. Clinical manifestations of systemic scleroderma arise from the diffuse deposition of collagen in the skin and visceral organs coupled with vascular injury and immunologic abnormalities. The skin becomes taut resulting in claw like appearance of fingers and a mask like appearance of the face. There are associated orofacial changes resulting in decrease in facial profile, rigidity of tongue and microstomia.

Keywords: Systemic Sclerosis, clinical features, case report.

*Correspondence author

Alebiosu C.O.

<http://orcid.org/0000-0001-6224-1782>

christopher.alebiosu@yale.edu

¹Yale University School of Medicine / Department of Medicine, Jackson F. Doe Regional Referral Hospital / A.M. Dogliotti College of Medicine, University of Liberia, Monrovia, Liberia.

²Department of Medicine, Jackson F. Doe Regional Referral Hospital, Tappita, Nimba County, Liberia.

Received: May 21, 2018

Accepted: June 11, 2018

Published: June 30, 2018

Research Journal of Health Sciences subscribed to terms and conditions of Open Access publication. Articles are distributed under the terms of Creative Commons Licence (CC BY-NC-ND 4.0). (<http://creativecommons.org/licenses/by-nc-nd/4.0>).

<http://dx.doi.org/10.4314/rejhs.v6i2.7>

Sclérodémie systémique : rapport d'enquête

*Alebiosu C.O.¹, Tadele D. Kebede.², James S.², Christopher D.²

Résumé

Un cas de sclérodémie systémique a été rapporté ; une brève analyse documentaire a mis l'accent sur les symptômes de la maladie et son traitement. La sclérodémie systémique est un trouble du tissu conjonctif touchant la peau, les vaisseaux sanguins et les organes viscéraux. Au Libéria, les données relatives à l'apparition de sclérodémie sont rares ou sous-estimées. Nous vous présentons le cas d'un patient souffrant de sclérodémie, observé en mai 2018 à l'hôpital régional Jackson F. Doe de Tappita, dans le comté de Nimba, au Libéria. L'objectif était de récolter des données sur la récurrence de la sclérodémie au Libéria. Les archives ont été passées en revue, en utilisant des mots clés comme sclérodémie, sclérose, Libéria, Afrique de l'ouest. Les bases de données consultées étant AJOL et Pubmed. Les manifestations cliniques de la sclérodémie systémique se traduisent par un dépôt dispersé de collagène sous l'épiderme au niveau des organes viscéraux. On ajoute à cela des lésions vasculaires et des anomalies immunologiques. La peau est plus tendue, ce qui fait que les doigts s'apparentent à des pinces, et le visage à un masque. On assiste donc à une évolution bucco-faciale qui se traduit par une diminution du profil facial, une rigidité de la langue et une microstomie.

Mots clés : sclérodémie systémique, symptômes, rapport d'enquête

*Correspondence author

Alebiosu C.O.

<http://orcid.org/0000-0001-6224-1782>

christopher.alebiosu@yale.edu

¹Yale University School of Medicine / Department of Medicine, Jackson F. Doe Regional Referral Hospital / A.M. Dogliotti College of Medicine, University of Liberia, Monrovia, Liberia.

²Department of Medicine, Jackson F. Doe Regional Referral Hospital, Tappita, Nimba County, Liberia.

Received: May 21, 2018

Accepted: June 11, 2018

Published: June 30, 2018

Research Journal of Health Sciences subscribed to terms and conditions of Open Access publication. Articles are distributed under the terms of Creative Commons Licence (CC BY-NC-ND 4.0). (<http://creativecommons.org/licenses/by-nc-nd/4.0>).

<http://dx.doi.org/10.4314/rejhs.v6i2.7>

INTRODUCTION

The scleroderma heterogeneous group of disorders is linked by the presence of thickened, sclerotic skin lesions. The condition is characterized by fibrotic changes of the skin, blood vessels, and visceral organs (1). Scleroderma occurs in two forms, localized and systemic forms. In the localized form (morphea), there will be involvement of the skin and subcutaneous tissue occasionally deeper tissues. In the systemic form, diffuse fibrosis of the skin and internal organs, primarily involving the blood vessels, gastrointestinal tract, lungs, heart, and kidneys (1).

Localized scleroderma can be divided into linear scleroderma ("en coup de sabre"), and localized and generalized morphea (2). The latter are characterized by patches of sclerotic skin that develop on the trunk and limbs at sites of previously normal texture. Morphea is localized scleroderma with involvement of the skin, subcutaneous tissue and at times deeper tissues. Diffuse fibrosis of the skin and internal organs occur in the systemic type, involving the blood vessels, gastrointestinal tract, lungs, heart, and kidneys. One of the main differences is that systemic sclerosis differs from morphea because it is accompanied by Raynaud's phenomenon, acrosclerosis and internal organ involvement (3,4,5).

Generally, scleroderma is seen in women between ages 30 and 50 with a prevalence rate of 250 per million (3,6). The incidence varies among populations with a report of 3.7 million per year in UK and Iceland, whereas, USA has an incidence of 18.7-22.8 million per year (7,8,9). Scleroderma appears under-reported among black Africans and these have mostly been in single case reports. The scleroderma in black Africa has the same clinical characteristics as those described in the literature (9,10,11), but its management is hampered in Africa not only due to the difficulties of access to care, but also to psychological and cultural contexts. Studies have confirmed the rarity of report of scleroderma in Africa. About the largest case series was from South Africa in a case study of 63 blacks living in a gold mine region (12).

Keita (13) reported only 35 cases of Systemic sclerosis in 10 years in Mali and Adelowo (14) in Nigeria had reported 14 cases in 5 years. Aka et al. in 2016 studied 217 cases of scleroderma in Côte d'Ivoire, and reported a prevalence of 0.08% in 2015 (15). Patients were predominantly women with a sex ratio (F/M) of 1.66/1. The mean age of patients was 25.35 years

for localized scleroderma and 33.70 years for systemic scleroderma. The Raynaud's syndrome was found in 3 of these patients. Adelowo et al. found two cases of Raynaud's phenomenon in a population of 14 patients (14). This confirms the rarity of this phenomenon in Africa (15) probably related to the warm tropical climate as it is triggered by the cold.

Genetic and environmental factors have been implicated as aetiological factors. A first-degree relative has a high probability of developing scleroderma. Environmentally induced scleroderma is characterized by the generally diffuse distribution of skin sclerosis in combination with a history of exposure to an agent suspected of precipitating scleroderma. Candidate initiating agents include vinyl chloride, epoxy resins, pesticides, and a number of organic solvents used in paints. Chemotherapeutic agents including taxanes have also been linked to development of scleroderma that may resemble that triggered by these other agents (16).

Clinically, Scleroderma causes various changes at the oral and facial tissues. The oral manifestations of scleroderma include fibrosis and rigidity of facial skin giving a mask-like appearance of the face. There are also fibrotic changes of structures within the mouth including the tongue, soft palate, larynx, salivary glands, and buccal mucous membrane leading to microstomia, dysarthria, dysphagia, and xerostomia. Periodontal manifestations including a loss of attached gingiva and multiple foci of recession may occur (5). The first specific clinical sign of scleroderma is the swelling on the skin of hands and fingers (17).

Radiographic changes in scleroderma patients are the widening of periodontal space, loss of lamina dura, and resorption of the mandibular angle (18). The diagnosis of scleroderma is clinical and is made by the presence of Raynaud's phenomenon, typical skin thickening and visceral involvement. Laboratory investigations are supportive. The goal of therapy is to improve quality of life by minimizing specific organ involvement and subsequent life-threatening disease. Hence, multiple drug therapy targeting the different pathogenetic mechanisms required.

The aim of this case report is to present some characteristics of a patient diagnosed as having Systemic Sclerosis and to create awareness to the under-reporting of this connective tissue disorder in Liberia.

CASE REPORT

A 48-year-old lady presented to the Jackson F Doe Memorial Referral Hospital complaining of a 12-year history of coarseness of the face, pigmentary skin changes involving the trunk associated with smallness and dryness of the mouth of four weeks duration. There was associated gradual reduction in the mouth orifice. There are no difficulty in tongue movement, speech, and swallowing. There is no dysphagia to solids or fluids. Patient reported episodes of gastro esophageal reflux with heartburn on an off within a year of presentation.

There is associated dry persistent cough associated with gradual weight loss, but no chest pain. There is stiffness of fingers of both hands but not the feet, associated pain when the weather is cold. No history of joint pain. She has also noticed a progressive hoarseness of her voice. There is no pruritus, hair changes or changes noticed in the eyes.

There are no changes in the bowel or urinary habit. There is no swelling of any part of the body including the face. She is neither a known hypertensive nor diabetic. Urinary D/N ratio is however 6/4, non-frothy. She stopped menstruating two years ago. There is no history suggestive of thyroid gland dysfunction or diabetes mellitus. The past medical, dental, and family history was non-contributory.

On general examination patient was conscious, co-operative moderately built with no signs of pallor. There was no palpably enlarged peripheral lymphadenopathy. Further examination showed a middle-aged lady with a characteristic beaklike facie and microstomia, paucity of facial wrinkles and traction alopecia. There are decreased number of wrinkles and distinct facial features because of the atrophy of ala nasi.

She had hypo and hyper-pigmented macules on the trunk, anteriorly and posteriorly in a characteristic 'salt-pepper pattern' (Fig 1). The skin on the forehead, forearm and the fingers were extremely difficult to pick. There were flexion deformities of the lateral three fingers of the right hand, and the index finger of the left hand. There were also healed pitting ulcers on the fingertips, which had deformed the digits (Fig 2). Vital signs are PR = 100bpm; 144/85mm/Hg, RR= 18cpm; T=36.5°C. Height = 158cm Weight = 49.8kg.

Complete Blood Count was essentially normal – total count of 8.4×10^3 : N57.5%, L29.1%, M9.4%, E2.71% and B1.3%. Platelets were 373×10^3 . The haematocrit was normal at

38.6% (Hb = 11.6g/dl). Urinalysis was essentially normal as well as the renal function tests. (Creatinine = 96.49mmol/l (1.091mg/dl), Urea = 24.88mg/dl). The chest x-ray (Fig 3) showed bilateral lung but predominantly right reticulonodular opacities in keeping with interstitial lung disease.

The patient did not carry out certain examinations (manometry, cardiac ultrasound and immunoassay) for financial reasons. A diagnosis of Systemic Sclerosis with secondary Sjögren syndrome was made. Patient was commenced on Prednisolone and mycophenolate 1gm bid.

DISCUSSION

The diagnosis of Systemic Sclerosis is mainly clinical and is made by the presence of Raynaud's phenomenon, typical skin thickening and at times visceral involvement. Laboratory investigations are usually supportive. This 48-year-old lady presented with 12-year history of coarseness of the face associated with characteristic facie and pigmentary skin changes of the trunk as well as deformities of the hands and Raynaud phenomenon.

The patient reported episodes of gastro esophageal reflux with heartburn within a year of her presentation without dysphagia to solids or fluids. It has been reported that 80% of patients with scleroderma present with symptoms in upper region of the body (19), manifesting as dysphagia and gastroesophageal symptoms. Others include trismus, decreases in facial wrinkles (due to skin fibrosis), orofacial telangiectasia and resorption of mandibular angle.

The patient has flexion deformities of the lateral three fingers of the right hand, index finger of the left hand and there were healed pitted ulcers on the fingertips, which deformed the digits (Fig 3). Resorption of the terminal phalanxes, short and claw-like fingers because of acro-osteolysis, ulcers on fingertips are common in patients with scleroderma (19,20).

There was also associated dryness of the mouth, associated with gradual reduction in the mouth orifice. Xerostomia might be seen in scleroderma due to the development of secondary Sjögren syndrome (1,3,20). The excessive collagen deposition in the cutaneous tissues around the mouth causes microstomia, which usually prevent the patient from opening and closing the mouth. Fibrosis of salivary glands leads to xerostomia, dysphagia, and subsequently periodontal infections (1, 6). This may lead to

higher incidence of dental caries. A high occurrence of dental caries as a result of xerostomia may be attributed to inadequate oral hygiene by virtue of sclerotic changes of the hands.

Systemic Sclerosis is an autoimmune disease in which there is no consensus on the treatment protocol (3,5,6). In patients who have both diffuse cutaneous and visceral involvement, the treatment intensity is usually dictated by the immunosuppressive therapies used to address visceral disease. Unfortunately, most of these treatments demonstrate only a modest benefit, at best, for skin thickening (2). For patients with progressive and diffuse skin involvement who do not have visceral involvement, methotrexate (MTX) or mycophenolate mofetil (MMF) is recommended, ideally therapy should be initiated within three years of disease onset (2). The use of cyclophosphamide is reserved for progressive skin involvement in patients who are refractory to treatment with either MTX or MMF, or have severe rapidly progressive skin thickening (2). For patients with systemic sclerosis refractory to treatments, other immune-modulatory agents such as intravenous immune globulin (IVIG) or rituximab are usually considered as adjuvant therapy (2).

There is a substantial increase in the risk of mortality in patients with systemic sclerosis. Mortality risk is related to presence of pulmonary fibrosis, pulmonary arterial hypertension, or cardiac causes (2). Other significant causes include renal disease, malignancy, gastrointestinal, and infectious causes.

In conclusion, Systemic Sclerosis is a multisystem organ disorder with oral, cutaneous and at times visceral involvement. Physicians should be more attentive to the potential risk factors for organ damage, particularly very early in the disease, even when the patients may not be symptomatic. Treatment should be initiated early.

Conflicts of Interest: The authors declare no conflict of interest.

Acknowledgements: The authors acknowledge the support of all the intern doctors, medical officer, physician assistant and the nursing staff of the Department of Medicine, Jackson F. Doe Regional Referral Hospital, Tappita, Nimba County, Liberia.

REFERENCES

- Albilia JB, Lam DK, Blanas N, Cloakie CM, Sándor GK. Small mouths big problems? a review of scleroderma and its oral health implications. *J Can Dent Assoc* 2007;73(9):831-836.
- Christopher P Denton, MD. Overview and classification of scleroderma disorders. May 2018, UpToDate.
- Cazal C, Sobral AP, Neves RF, Freire Filho FW, Cardoso AB, da Silveira MM. Oral complaints in progressive systemic sclerosis: two case reports. *Med Oral Patol Oral Cir Buccal* 2008;13(2):114-118.
- de Figueiredo MA, de Figueiredo JA, Porter S. Root resorption associated with mandibular bone erosion in a patient with scleroderma. *J Endod* 2008;34(1):102-103.
- Özgen M, Koca SS. Sklerodermanın etiopatogenezi ve güncel tedavisi. *Fırat Üniv Sağlık Bil Tıp Derg* 2010;24(1):69-76.
- Dedic A, Pasalic A, Hodzic M, Basovic S, Avdic M, Pasic E. Scleroderma--from the aspect of dental medicine. *Med Arh* 2011; 65(6):368-370.
- Medsger TA Jr, Masi AT. Epidemiology of systemic sclerosis. *Ann Intern Med* 1971; 74:714-721.
- Michet CJ Jr, McKenna CH, Elveback LR et al. Epidemiology of systemic lupus erythematosus and other connective tissue diseases in Rochester, Minnesota, 1950 through 1979. *Mayo Clin Proc* 1985; 60:105-113.
- Steen VD, Oddis CV, Conte CG et al. Incidence of systemic sclerosis in Allegheny County, Pennsylvania. A twenty year study of hospital diagnosed cases. 1963-1982. *Arthritis Rheum* 1997;40:441-445.
- Laing TJ, Gillepsie BW, Toth MB et al. Racial differences in scleroderma among women in Michigan. *Arthritis Rheum*. 1997; 40:734-742
- Mayes MD, Lacey N Jr, Beebe-Dimmer J, Gillepsie BW, Cooper B, Laing TJ, Schottenfeld D. Prevalence, incidence, survival and disease characteristics of systemic sclerosis in a large US population. *Arthritis Rheum* 2003;48:2246-2255.
- Polednak AP. Connective tissue responses in blacks in relation to disease: further observations. *Am J Phys Anthropol* 1987;74(3):357-371.
- Kéita S, Mahé A, Traoré DB. Etude rétrospective de 35 cas de sclérodémie systémique à Bamako, Mali. *Mali Medical* 1996;11: 21-27.
- Adelowo OO, Oguntona S. Scleroderma (systemic sclerosis) among Nigerians. *Clin Rheumatol* 2009;28: 1121-1125.
- BR Aka, A. Diabaté, M. Kaloga, HS Kourouma, B. Vagamon, I. Gue. Scleroderma in a Black African Subject: A Study of 217 Cases in Cote d'Ivoire. *J Clin Exp Dermatol Res* 2017;8: 398.
- Itoh M, Yanaba K, Kobayashi T, Nakagawa H. Taxane-induced scleroderma. *Br J Dermatol* 2007; 156:363.
- Dedic A, Pasalic A, Hodzic M, Basovic S, Avdic M, Pasic E. Scleroderma--from the aspect of

dental medicine. *Med Arh* 2011;65(6):368-370.18. White SC, Frey NW, Blaschke DD, Ross MD, Clements PJ, Furst DE, Paulus HE. Oral radiographic changes in patients with progressive systemic sclerosis (scleroderma). *J Am Dent Assoc* 1977; 94(6):1178-1182.

19. Yücel ÖÖ, Ercan E. Periodontal conditions and mucogingival surgical treatment of a patient with scleroderma. *Hacettepe Diş Hekim Fak Derg* 2009;33(1):41-46.20. Neville BW, Damm DD, Allen CM, Bouquot DE. *Oral and maxillofacial pathology*. 3rd ed, St. Louis, Missouri: Saunders Elsevier, 2009, p.798-801.

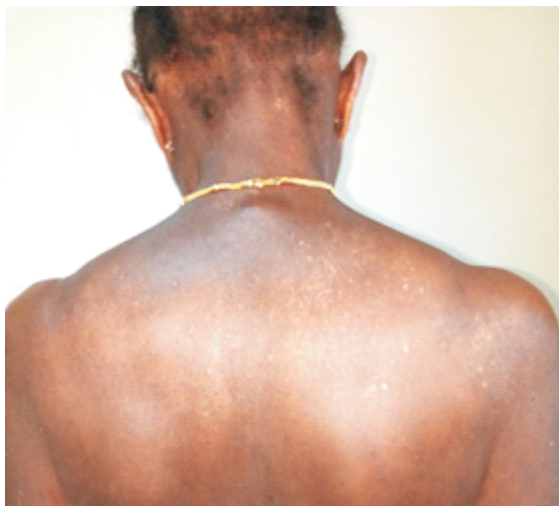

Figure 1. Shows hypo and hyper-pigmented macules on the trunk, in a characteristics 'salt-pepper pattern'.

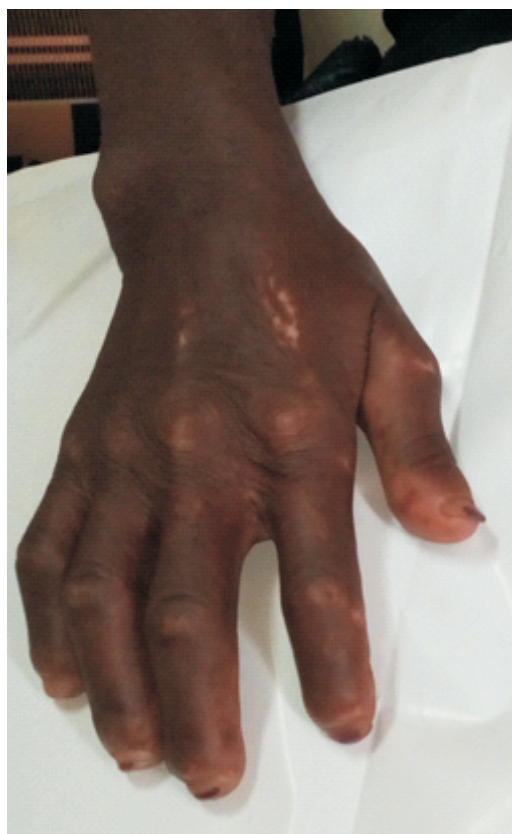

Figure 2. Shows healed pitting ulcers on the finger-tips, with deformed the digits.

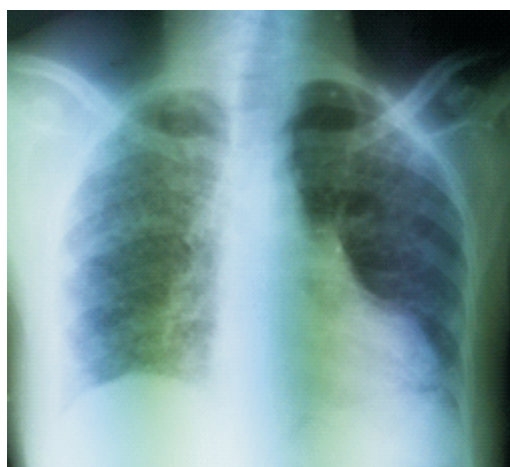


Figure 3. Shows bilateral lung (but predominantly right) reticulonodular opacities in keeping with interstitial lung disease.